Pedunculated colorectal polyps with heads ≤ 1 cm in diameter can be resected using cold snare polypectomy

T. Kudo[1,2], A. Horiuchi[1], I. Horiuchi[1], M. Kajiyama[1], A. Morita[1], N. Tanaka[1]

(1) Digestive Disease Center, Showa Inan General Hospital, Komagane, Japan ; (2) Department of Pediatrics, Juntendo University Faculty of Medicine, Tokyo, Japan.

Abstract

Background and study aims: **Cold snare polypectomy (CSP) is not recommended for the resection of pedunculated colorectal polyp. The aim of this study was to examine the adequacy of CSP compared to hot snare polypectomy (HSP) for the complete resection of pedunculated polyps with heads ≤ 1 cm in diameter.**

Patients and methods: **This was a retrospective study of a cohort of consecutive outpatients who had resection of pedunculated polyps with heads 6-10 mm in diameter using either dedicated CSP or HSP from 2014 through 2019. The primary outcome measure was occurrence of delayed bleeding. Secondary outcome measures included total procedure time, en bloc resection rate, immediate bleeding, and number of clips used.**

Results: **415 patients with 444 eligible polyps were enrolled; the CSP group (363 patients; 386 polyps) and HSP group (52 patients; 58 polyps). Patient characteristics, polyp characteristics and en bloc resection rate were similar between groups. The mean total procedure time and mean number (range) of hemostatic clips/patient used were significantly lower with CSP than with HSP (18± 8 min vs. 25± 9 min, P<0.001; 1.1 ± 0.6 (1-3) vs.3.1 ± 1.6 (1-5), respectively, P<0.001). Delayed bleeding occurred significantly less frequently in the CSP, 0% (0/363 vs.3.8% (2/52) in the HSP group (P<0.001), although immediate bleeding was significantly higher in CSP than HSP (84% (325/386) vs. 12% (7/58), P<0.001).**

Conclusion: **Pedunculated colorectal polyps with heads ≤ 1 cm can be removed using CSP, which has several advantages over HSP.** (Acta gastroenterol. belg., **2021**, 84, **411-415**).

Key words: colorectal polyp, pedunculated polyp, cold snare polypectomy, hot snare polypectomy.

Introduction

Colonoscopy is commonly used to detect and remove colorectal polyps with the goal of reducing the incidence and mortality of colorectal cancer (1,2). In order to achieve this goal, colonic polypectomy techniques including cold snare polypectomy have spread rapidly in the medical world, contributing to the achievement of clean colon. However, cold snare polypectomy is not recommended for the resection of pedunculated colorectal polyps, although the reasons why have not thus far been clarified (3,4).

In January 2014, we started to resect pedunculated polyps with heads ≤ 1 cm in diameter using a dedicated cold snare. We first reported that the complete resection rate was significantly greater with the dedicated cold snare than with the traditional cold snare (91% vs. 79%, P = 0.015), with a marked difference in 8- to 10-mm polyps, both flat and pedunculated (5). In addition, in our previous study of resection of pedunculated polyp (≤ 1 cm), a dedicated cold snare was superior to a traditional cold snare with regard to occurrence of delayed bleeding 0% (0/72) vs. 2% (2/100) (P=0.63) even in patients with antithrombotic therapy (6). Moreover, hemostatic clips were used significantly less frequently with dedicated cold snares than with traditional cold snares (i.e., in 13/72 (18%) patients and 33/100 (33%), respectively; P=0.044) (6).

Based on our experience over six years, we speculated that a cold snare polypectomy technique using a dedicated cold snare could reliably achieve the complete resection of all pedunculated polyps with heads ≤ 1 cm in diameter. The aim of this study was to examine the adequacy of the cold snare polypectomy technique using a dedicated cold snare for the complete resection of pedunculated colorectal polyps with heads ≤ 1 cm in diameter compared to hot snare polypectomy.

Patients and methods

Study design and setting

This was a retrospective study of a collected cohort from consecutive outpatients who had resection of pedunculated polyps with heads 6-10 mm in diameter using either a dedicated cold snare polypectomy or hot snare polypectomy. The study was done at the Showa Inan General Hospital in Japan and was carried out in accordance with the Declaration of Helsinki. The Institutional Review Board of the hospital approved the retrospective chart review study protocol (No. 2019-08) on January 15, 2020. All authors had access to the study data and reviewed and approved the final manuscript. The study is reported according to the STROBE guidelines.

Subjects

Subjects referred and scheduled for screening, surveillance, or diagnostic colonoscopy were enrolled between January 2014 and December 2019; during this time 4529 patients underwent colonoscopic polypectomy. As it was difficult to assess the shape or size of polyps < 5 mm in detail, 415 patients in whom pedunculated polyps with heads 6-10 mm in diameter were resected using either

Correspondence to : Akira Horiuchi, MD, Digestive Disease Center, Showa Inan General Hospital, 3230 Akaho, Komagane 399-4117, Japan. Phone: +81-265-82-2121. Fax: +81-265-82-2118.
E-mail: horiuchi.akira@sihp.jp

Submission date : 02/11/2020
Acceptance date : 14/02/2021

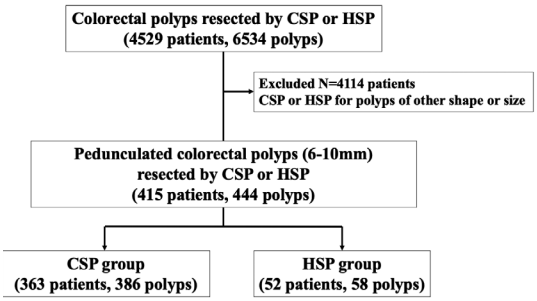

Fig. 1. — Study flow diagram : cold snare polypectomy (CSP) in 363 patients and hot snare polypectomy (HSP) in 52 patients were included in the final analysis.

cold or hot snare polypectomy were enrolled in this study (Fig. 1). The selection of either cold snare or hot snare polypectomy was based on the endoscopist's preference. In this study, we counted each pedunculated polyp that was resected in each patient, even if two or more polyps were resected during the procedure. Antithrombotic agents, including antiplatelet agents and anticoagulants, were not discontinued in patients who were selected for this study according to the basic policy of our endoscopy unit. Exclusions included age less than 20 years, pregnant, American Society of Anesthesiologists (ASA) class III or IV, overweight (body weight >100 kg), or allergic to the drugs used or their components (soybeans or eggs).

Endoscopists and equipment

All procedures were performed by one of five experienced endoscopists who have each conducted >3,000 colonoscopies. The high-definition EC-L600ZP7 endoscope that is part of a LASEREO endoscopic system (Fujifilm Co, Tokyo, Japan) or a pediatric variable-stiffness colonoscope (PCF-Q260AZI) with video processor system (EVIS LUCERA CV-260SL; Olympus, Tokyo, Japan) was used for all patients. A transparent hood (Olympus D-201-12704) was attached to the tip of the colonoscope prior to the procedure (7). The distal end of the cap was placed so that it extended approximately 2 mm beyond the tip of the colonoscope. Retroflexion in the rectum was routinely performed. All patients were prepared using 2 L of polyethylene glycol electrolyte lavage solution plus ascorbic acid (EA Pharmaceutical Co, Tokyo, Japan). Nurse-administered propofol sedation (Nichi-Iko, Tokyo, Japan) was used for all procedures (8).

Polypectomy technique

Two kinds of dedicated cold snares (Exacto™ Cold Snare, US Endoscopy, Mentor, OH, USA; Captivator™ COLD snare, Boston Scientific, Natick, MA, USA) were exclusively used for cold snare polypectomy. Each has a maximum snare diameter of 9 or 10 mm, and the snare wire diameter in both is 0.30 mm. The sheath diameter of each snare is 2.4 mm. On the other hand, hot snare polypectomy was performed using a

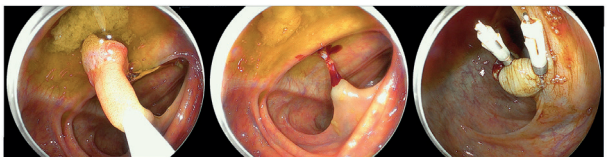

Fig. 2 — (Right) A pedunculated colorectal polyp was resected using cold snare polypectomy. (Center) Immediate bleeding occurred shortly after the resection. (Left) Hemostatic clipping was performed.

traditional polypectomy snare with a loop size of 13 mm (Captivator™ Small Hex; Boston Scientific, Natick, MA, USA) under the electrosurgical unit. The VIO300D (Erbe Elektromedizin, Tuebingen, Germany) was used as the power source for the electrical resection in hot polypectomy cases. The monopolar mode (AUTO CUT, effect 3, 40 W) and foot pedal are typically used for hot snare polypectomy at our endoscopy unit.

Irrespective of cold or hot snare polypectomy procedure, the endoscope was rotated to align the polyp with the instrument channel at 6 o'clock, and the pedunculated polyps were resected. Especially, the middle portion of the stalk was transected with the cold snare without ripping off the mucosa using extra mechanical force by pulling back the snare against the endoscope, resulting in the lower part of the stalk with a blood vessel leaving (Fig. 2 left).

If residual polyp was seen at the polypectomy site, it was resected again. The transected small polyps were sucked into a trap (eTrap®, US Endoscopy, Mentor, OH, USA). Larger resected polyps were retrieved using forceps without the use of the endoscopic suction channel in order to avoid fragmenting the samples. We did not perform submucosal injection of saline before polyp removal. In our practice, prophylactic clipping after polyp removal is not routinely performed because prophylactic use of hemostatic clips has not proven to be effective for prevention of delayed bleeding after conventional polypectomy.

However, based on our experiences prophylactic clipping was used following the resection of pedunculated polyps with heads 6-10 mm in diameter to prevent delayed bleeding, irrespective of cold or hot snare polypectomy procedure. In particular, hemostatic clipping was carried out during the procedure for immediate bleeding, defined as spurting or oozing that continued for more than 30 s (Fig. 2 center, right).

When we encountered polyps other than pedunculated polyps with heads 6-10 mm in diameter, cold or hot snare polypectomy or endoscopic mucosal resection was used based on the endoscopists' judgement.

Data collection

Time taken to reach the cecum, intubation rate of the terminal ileum, total procedure time, the location, size, shape and pathology of all polyps, antithrombotic agents used, and number of hemostatic clips used were

prospectively recorded. The left side of the colon was defined at or distal to the splenic flexure. The size of the head in pedunculated polyps was determined using a biopsy forceps with a 2.2-mm outer diameter (Radial Jaw 3; Boston Scientific, Natick, MA, United States) or a 9- or 10-mm cold dedicated snare wire. Polyps were measured in increments of 1 mm. All patients who underwent polypectomy visited our hospital two weeks after the procedure to learn the pathological results of removed polyps. Adverse events and all gastrointestinal symptoms within two weeks after polypectomy were prospectively recorded.

Pathological examination

Clinical information regarding polypectomy technique in this study remained completely blinded to the pathologist (KS). After removal, excised specimens were mounted with pins on Styrofoam plates and fixed in 10% formalin. They were examined grossly, and following sectioning they were examined using hematoxylin and eosin staining. The resection was defined as histologically complete if lateral and vertical margins were free from neoplasia tissue.

Outcome variables

The primary outcome measure was occurrence of delayed bleeding. Secondary outcome measures included total procedure time, en bloc resection rate, immediate bleeding, and the number of clips used. Delayed bleeding was defined as bleeding within two weeks after polypectomy that required hemostatic treatment. When delayed bleeding was suspected without a decrease in hemoglobin, the bleeding was judged to be "slight" post polypectomy bleeding, which was designated as hematochezia. Immediate bleeding requiring hemostatic clipping was defined as spurting or oozing that continued for more than 30 s.

Statistical analysis

Data are presented as means and standard deviations. The chi-square test, with Yates' correction for continuity where appropriate, was used for comparison of categorical data. Fisher's exact test was used when the numbers were small. For parametric data, Student's *t*-test was used when two means were compared. Non-parametric data were analyzed by Wilcoxon rank sum test. A value of $p < 0.05$ was regarded as significant. Statistical analysis was performed using GraphPad Prism Version 8.4.1 (GraphPad Software Inc.).

Results

415 patients with 444 eligible polyps were enrolled: the cold snare polypectomy group had 363 patients (386 polyps), and the hot snare polypectomy group had 52 (58 polyps). Demographics, anticoagulant agent use (warfarin), indications and quality of colon preparation were comparable (Table 1). However, the mean total procedure time was significantly shorter with cold snare polypectomy than with hot snare polypectomy (18± 8 min vs. 25± 9 min, P<0.001). In addition to the location and pathology of pedunculated polyps, the mean head size of resected pedunculated polyps and en bloc resection rate were similar between groups (8.2± 2.3 mm vs. 8.5± 2.8 mm, P=0.76; 100% vs. 100%) (Table 2). The biggest size of stalk that was removed by cold snaring was almost twice as the size (2.4 mm) of sheath diameter of each cold snare. Both the ratio of patients who required hemostatic clips and the mean number

Table 1. — **Baseline and procedure characteristics of patients who had pedunculated colorectal polyps resected using either cold snare polypectomy or hot snare polypectomy**

Variables	CSP	HSP	*P values*
Number of patients	363	52	
Mean [SD] age (yr)	66 [11]	65[13]	0.72
Gender (male), n (%)	207 (57)	29 (56)	0.89
Anticoagulant agent (warfarin) use, n (%) 21 (6)	5(10)	0.29	
Indications, n (%)			
Screening/surveillance	182 (50)	25 (48)	0.93
Hemo-positive stool	156 (43)	24 (46)	
Other	25 (7)	3 (6)	
Boston Bowel Preparation Scale score Median (IQR)	8.0 (6.0-9.0)	8.0 (6.0-9.0)	0.65
Cecum intubation rate (%)	100	100	
Mean [SD] cecal intubation time (min)	5.5[6]	5.7 [8]	0.34
Mean [SD] total procedure time (min)	18[8]	25 [9]	<0.001

IQR, interquartile range; CSP, cold snare polypectomy; HSP, hot snare polypectomy.

Table 2. — **Characteristics of pedunculated colorectal polyps resected with either cold snare polypectomy or hot snare polypectomy**

Variables	CSP	HSP	*P values*
Total number of polyps removed	386	58	
Location, n (%)	0.56		
Right colon	162 (42)	22 (38)	
Left colon	224 (58)	36 (62)	
Pathology, n (%)			0.86
Invasive cancer	0	0	
Intramucosal cancer	2 (0.5)	2 (3.4)	
Adenoma	317 (82)	55 (94.8)	
Traditional serrated adenoma	2 (0.5)	0	
Hyperplastic polyp	65 (17)	0	
Sessile serrated lesion	0	0	

CSP, cold snare polypectomy; HSP, hot snare polypectomy.

Table 3. — **Outcomes in patients who had pedunculated colorectal polyps resected using either cold snare polypectomy or hot snare polypectomy**

Variables	CSP	HSP	*P values*
Number of patients	363	52	
Total number of polyps removed	386	58	
Size of the head of pedunculated polyp Mean [SD] (range)	8.2 [2.3] (6-10)	8.5 [2.8] (6-10)	0.76
En bloc resection rate, n (%)	386 (100)	58(100)	
Number of patients who used hemostatic clips, n (%)	314 (87)	52 (100)	0.0048
Number of hemostatic clips/ patient used Mean [SD] (range)	1.1 [0.6] (1-3)	3.1 [1.6] (1-5	<0.001

CSP, cold snare polypectomy ; HSP, hot snare polypectomy.

Table 4. — **Adverse events in patients who had pedunculated colorectal polyps resected using either cold snare polypectomy or hot snare polypectomy**

Variables	CSP	HSP	*P values*
Immediate bleeding/polyp, n (%)	325/386 (84)	7/58 (12)	<0.001
Hematochezia/patient, n (%)	3/363 (0.8)	0/52 (0)	0.51
Delayed bleeding/patient, n (%)	0/363 (0)	2/52 (3.8)	<0.001
Perforation/patient, n (%)	0/363 (0)	0/52 (0)	

CSP, cold snare polypectomy ; HSP, hot snare polypectomy. Hematochezia (mild uninvestigated bleeding) and delayed bleeding within two weeks after each polypectomy were recorded.

(range) of hemostatic clips/patient were significantly lower with cold snare polypectomy than with hot snare polypectomy (87% vs. 100%, P=0.0048; 1.1 ± 0.6 (1-3) vs.3.1 ± 1.6 (1-5), P<0.001) (Table 3). Delayed bleeding following cold snare polypectomy occurred significantly less frequently (0/363), 0% with cold snare polypectomy vs. 3.8% (2/52) with hot snare polypectomy (P<0.001), although immediate bleeding was significantly higher in the cold snare group than the hot snare (84% (325/386) vs. 12% (7/58), P<0.001) (Table 4). Delayed bleeding occurred within 5 days while hematochezia (mild uninvestigated bleeding) occurred within 48 hours after each polypectomy. No perforation occurred in either group.

Discussion

We confirmed that complete en bloc resection was achieved in 100% of cases for pedunculated colorectal polyps with heads 6-10 mm in diameter by a dedicated cold snare polypectomy with several advantages, including shorter total procedure time, fewer hemostatic clips used, and lower delayed bleeding compared to hot snare polypectomy. Although hemostatic clipping for immediate bleeding is more frequently required following cold snare polypectomy, delayed bleeding following this procedure was significantly decreased compared to hot snare (0% (0/363) vs. 3.8% (2/52), P<0.001). The rate of delayed bleeding after cold snare polypectomy was 0%, irrespective of fewer mean hemostatic clip usage (cold, 1.1 ± 0.6 (range, 1-3) vs. hot, 3.1 ± 1.6 (range, 1-5), P<0.001).

The longer total procedure time with hot snare polypectomy likely relates to the need to prepare electrocautery equipment required for hot snare polypectomy. In addition, prophylactic clipping was used more often in the hot snare polypectomy group than in the cold snare polypectomy group. At least 1 clip was used in 87 % of cases after cold snare polypectomy while in 100 % after hot snare polypectomy. More clips (range, 1-5) were used for the prevention of delayed bleeding by hot snare polypectomy, although the number of clips used was not related to the frequency of delayed bleeding.

Our previous study including the resection of pedunculated colorectal polyps showed that delayed bleeding requiring hemostasis occurred significantly less commonly after cold snare than hot snare polypectomy, despite continuation of anticoagulants (0% vs.14%, P=0.027), and that injured submucosal arteries were seen less frequently following cold snare polypectomy (22% vs. 39%, P=0.023) (11). The present data on the rate of delayed bleeding (0%) after a dedicated cold snare polypectomy was in good agreement with our previous findings (6,12).

In addition, with regard to pedunculated polyps there is no evidence on pathologic examination showing the difference in cold snare polypectomy techniques. However, our previous study compared two different types of snare (dedicated cold vs. traditional snare) for cold snaring and histologically injured arteries present in the submucosal layer of non-pedunculated polyps in both groups (5). The prevalence of damaged arteries was less with the thinner especially designed cold snare (3.1% vs. 6.7%, P=0.24), although the difference was not significantly different. We speculated that our transecting technique using the dedicated cold snare would cause less delayed bleeding than with the traditional snare.

On the other hand, the negative issue of management of immediate bleeding following cold snare polypectomy should be considered. We frequently encountered immediate bleeding requiring hemostatic clipping following the resection of pedunculated polyps using cold snare polypectomy. Therefore, it was essential for the endoscopist to acquire the skill to stop immediate bleeding promptly after cold snare polypectomy using hemostatic clips. Two of 5 endoscopists may have avoided the frequent immediate bleeding observed after cold snare polypectomy, resulting in hot snare polypectomy was chosen in the majority of 52 patients.

When pedunculated polyps with heads 6-10 mm in diameter enrolled in this study were resected with the dedicated cold snare, hemostatic clipping was required

because immediate bleeding continued > 30 seconds. On the other hand, hemostatic clipping or prophylactic clipping was not necessarily required for smaller pedunculated polyps with heads ≤ 5mm in diameter which were not enrolled in this study.

The results of this study thus corresponded to those of recent studies in which cold snare polypectomy enabled complete resection of pedunculated polyps of less than 1 cm (9,10). Our study confirmed the complete resection of pedunculated polyps with heads 6–10 mm in diameter could be achieved by a dedicated cold snare polypectomy technique, irrespective of the size of the stalk. On the other hand, recent guidelines recommend that all pedunculated polyps should be resected by hot snare polypectomy (3,4). We suspect that the proposal was based on previous reports in which cold snare polypectomy was performed using the traditional polypectomy snare. We would propose that cold snare polypectomy using a dedicated cold snare should be further extended to the resection of pedunculated polyps with heads ≤ 1 cm in diameter, irrespective of the size of stalk. On the other hand, cold snare polypectomy has been applied for non-pedunculated colon polyps larger than 10 mm with or without submucosal injection (13).

This study has some limitations. The analysis was retrospective, although the data were collected prospectively. It is possible, however, that there was bias due to operator-independent and inclusion bias. Potentially, size of head measurement in pedunculated polyps can be affected by many factors, such as acces-sories, assistants, and endoscopists' skill. In addition, using a sheath diameter (2.4 mm) or snare size (9 or 10 mm) as a guide for polyp measurement may not have been precise to the level of 1 mm. We also examined only two specially designed cold snares. The results will need to be confirmed in multicenter studies using different populations and cold snares.

In conclusion, colorectal pedunculated polyps with heads 6–10 mm in diameter can be removed by cold snare polypectomy using a dedicated cold snare with several advantages over hot snare polypectomy. We would propose that guidelines recommending a dedicated cold snare polypectomy should be extended to the complete resection of colorectal pedunculated polyps with heads ≤ 1 cm in diameter.

Conflicts of interest

The authors declare no conflicts of interest for this article and have no funding to declare..

References

1. WINAWER SJ, ZAUBER AG, HO MN, O'BRIEN MJ, GOTTLIEB LS, STERNBERG SS, *et al.* Prevention of colorectal cancer by colonoscopic polypectomy. The National Polyp Study Workgroup. *N. Engl. J. Med,* 1993, **329** : 1977-1981.
2. CITARDA F, TOMASELLI G, CAPOCACCIA R, BARCHERINI S, CRESPI M, Italian multicentre study group. The Italian Multicentre Study Group: Efficacy in standard clinical practice of colonoscopic polypectomy in reducing colorectal cancer incidence. *Gut,* 2001, **48** : 812-815.
3. FERLITSCH M, MOSS A, HASSAN C, BHANDARI P, DUMONCEAU JM, PASPATIS G, *et al.* Colorectal polypectomy and endoscopic mucosal resection (EMR): European Society of Gastrointestinal Endoscopy (ESGE) clinical guideline. *Endoscopy,* 2017, **49** : 270-297.
4. KALTENBACH T, ANDERSON JC, BURKE CA, DOMINITZ JA, GUPTA S, LIEBERMAN D, *et al.* Endoscopic removal of colorectal lesions-recommendations by the US Multi-Society Task Force on Colorectal Cancer. *Gastroenterology,* 2020, **158** : 1095-1129.
5. HORIUCHI A, HOSOI K, KAJIYAMA M, TANAKA N, SANO K, GRAHAM DY. Prospective, randomized comparison of 2 methods of cold snare polypectomy for small colorectal polyps. *Gastrointest. Endosc.,* 2015, **82** : 686-692.
6. MAKINO T, HORIUCHI A, KAJIYAMA M, TANAKA N, SANO K, MAETANI I. Delayed bleeding following cold snare polypectomy for small colorectal polyps in patients taking antithrombotic agents. *J. Clin. Gastroenterol.,* 2018, **52** : 502-507.
7. HORIUCHI A, NAKAYAMA Y, KAJIYAMA M, KATO N, ICHISE Y, TANAKA N. Benefits and limitations of cap-fitted colonoscopy in screening colonoscopy. *Dig. Dis. Sci.*, 2013, **58** : 534-539.
8. SATO M, HORIUCHI A, TAMAKI M, ICHISE Y, KAJIYAMA M, YAMAMOTO Y, *et al.* Safety and Effectiveness of Nurse-Administered Propofol Sedation in Outpatients Undergoing Gastrointestinal Endoscopy. *Clin. Gastroenterol. Hepatol.,* 2019, **17** : 1098-1104.
9. ARIMOTO J, CHIBA H, ASHIKARI K, FUKUI R, TACHIKAWA J, SUTO T, *et al.* Safety and efficacy of cold snare polypectomy for pedunculated (Ip) polyps measuring less than 10 mm in diameter. *Int. J. Colorectal Dis.,* 2020, **35** : 859-867.
10. ARIMOTO J, CHIBA H, ASHIKARI K, FUKUI R, TACHIKAWA J, OKADA N, *et al.* Management of less than 10-mm-sized pedunculated (Ip) polyps with thin stalk: hot snare polypectomy versus cold snare polypectomy. *Dig. Dis. Sci.* 2020, Jul 4. doi : 10.1007/s10620-020-06436-7. Online ahead of print.
11. HORIUCHI A, NAKAYAMA Y, KAJIYAMA M, TANAKA N, SANO K, GRAHAM DY. Removal of small colorectal polyps in anticoagulated patients: a prospective randomized comparison of cold snare and conventional polypectomy. *Gastrointest. Endosc.* 2014, **79** : 417-423.
12. YABE K, HORIUCHI A, KUDO T, HORIUCHI I, ICHISE Y, KAJIYAMA M, *et al.* Risk of gastrointestinal endoscopic procedure-related bleeding in patients with or without continued antithrombotic therapy. *Dig. Dis. Sci.* 2020 Jun 16. do i: 10.1007/s10620-020-06393-1. Online ahead of print.
13. VAN OVERBEKE L, ILEGEMS S, MERTENS G, MORTIER L, VAN DONGEN J, VERBEKE L, *et al*. Cold snare endoscopic resection of nonpedunculated colorectal polyps larger than 10 mm. A retrospective series. *Acta Gastroenterol. Belg.* 2019, **82** : 475-478.